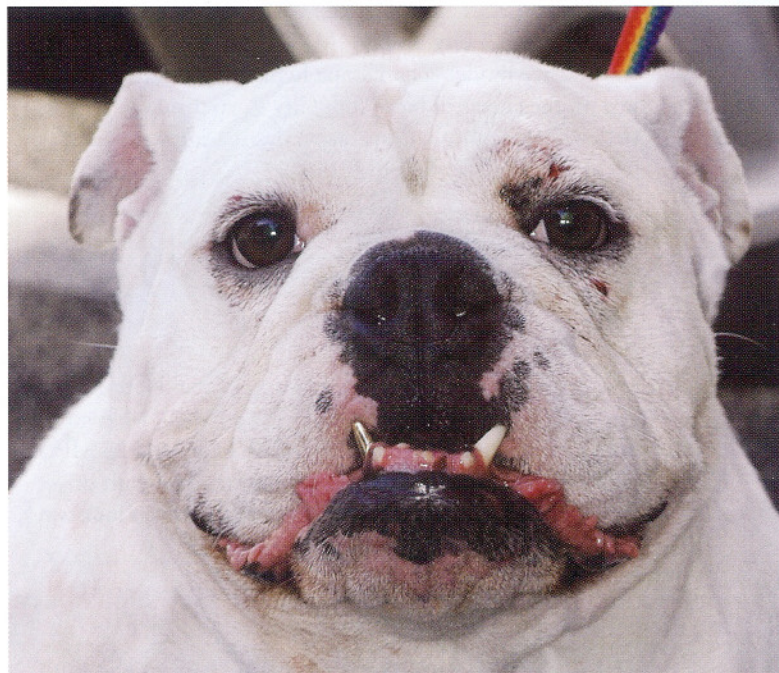


# Keeping the Sparkle in Your Dog's Smile

## Cosmetic Dental Surgery Has Gone To The Canines



**C**oconut certainly knows how to make an entrance. The five year old English Bulldog lights up every room, thanks to her new eye-catching gold crown on her canine tooth. Coconut's proud owner, Byron Lopez, will tell you his motivation for fitting her with a gold crown occurred after she fractured it and needed a root canal performed. But he's the first to admit that it is quite the conversation-starter for a single guy at local dog parks on the West side of Los Angeles. In a town known for its trend-setting cosmetic surgery and dentistry, LA pet owners are also seeking cosmetic alternatives to update their pooches' smile.

Despite a fair amount of requests for gold or porcelain-fused-to-metal crowns "caps", all-ceramic bridges and dental implants to replace missing teeth, Dr. Anson J. Tsugawa, a board-certified veterinary dentist at the California Animal Hospital Medical and Surgical Group in Los Angeles, says that he is dedicated mostly to treating more common oral ailments in dogs and cats. "An alarming 80% of dogs and 70% of cats show signs of oral disease by three years of age." In addition to being the most common disease in the dog and

cat, periodontal disease, commonly referred to as "gum disease", is also the most common cause of tooth loss. Its potential effects on systemic health (heart, lung, liver and kidney) have also been widely reported. Other oral conditions in the dog and cat include fractured teeth, and in cats, the painful "cavity-like" lesions known as feline odontoclastic resorption lesions or FORLs. The high prevalence of oral diseases in the dog and cat underscores the importance of seeking out quality dental care.

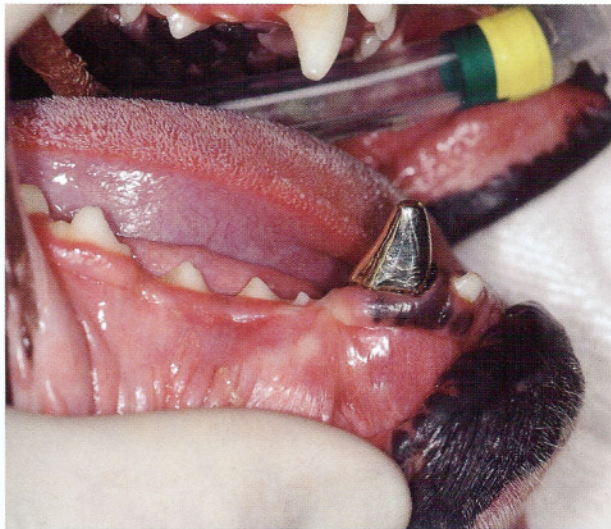
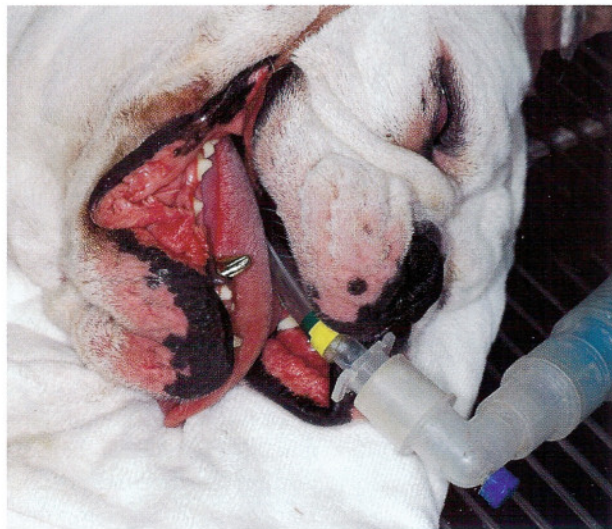### *How do I know if my dog or cat is suffering from dental disease?*

Many dogs and cats do not exhibit obvious signs of oral discomfort—decreased appetite, drooling, dropping food or preferentially chewing on one side of the mouth—until the very latter stages of oral disease. Without a well-defined oral healthcare regimen for your pet that includes both professional hygiene visits and regular at-home care, the early, more manageable stages of disease may go undiagnosed and untreated.

Periodontal disease is an infection caused by the accumulation of bacterial plaque on the surfaces of teeth. The bacteria in plaque results in inflammation of the gums (gingivitis) and can destroy the bone (periodontitis) around the tooth root. Tooth-brushing mechanically removes plaque and can reverse gingivitis and reduce the severity of periodontitis. Tartar or calculus is hardened plaque and is not easily removed by brushing, it must be removed with dental instruments. "We all have busy lives, and basically, with zero effort by the client, a diet can be introduced that is both beneficial from a dental standpoint and also nutritionally balanced."

When periodontal disease is left untreated, tooth loss becomes a reality for many pets. Many clients are shocked that their family veterinarian has advised extraction for a compromised tooth. This indeed may seem a drastic option, but sometimes a crucial one.





### *How is periodontal disease diagnosed?*

The severity of periodontal disease is not always obvious upon an initial awake oral examination by a veterinarian. "Most dental procedures in animals require sedation and/or anesthesia. Hopefully through client education, some of the fear associated with anesthesia can be allayed and the necessity for these procedures can be better understood." A complete oral examination requires that the patient remain completely still, and includes the evaluation of all surfaces of the oral cavity, assessment of pocket depth around each tooth, inspection of the undersurface of the tongue, tonsils in the back of the throat and palpation of lymph nodes.

### *Proper dental cleaning*

Dental cleanings performed without anesthesia only address plaque and calculus on the accessible outer surfaces of teeth. This leaves the tooth surfaces very rough and more prone to accumulation of plaque. In order for a dental cleaning to be of therapeutic value, all tooth surfaces, not just the crowns, and especially those surfaces underneath the gums (subgingival), must be cleaned and subsequently polished.

### *The fractured tooth*

Dogs may accidentally fracture their teeth by chewing on bones or the metal bars of a cage. A proper anesthetized oral examination can identify teeth that are fractured. The major teeth used for chewing/shearing food are in the back of the mouth and are often difficult to see without excessively pulling back a dog's lips. The fractured tooth may also be hidden underneath a layer of calculus and not readily apparent until the teeth are cleaned. Fractured teeth are ideally treated by root canal, so that the tooth can be saved, but may have to be extracted when the fracture is severe.

### *"Cavity-like" lesions in cats*

Feline odontoclastic resorption lesions (FORLs) are painful cavity-like lesions in the cat that originate on the root surface of the tooth. Because the early lesion is localized to the roots, early lesions can only be diagnosed with the aid of dental x-rays. As the disease progresses, the crown may become involved and eventually dislodged. FORLs are the second leading cause of tooth loss in cats. The origin of these lesions is still unknown. FORLs do not respond to conventional tooth fillings and extraction is often the only way to eliminate the discomfort associated with these lesions. Cats that are diagnosed with FORLs are predisposed to the development of additional lesions and should be re-evaluated on a regular basis by a veterinarian.

### *"Gold standard" oral hygiene*

There are many differences between veterinary and human health care, and it is usually inappropriate to make a direct comparison between the two fields without careful consideration. Dental health care is a rare exception, and the high standard you would expect for the care of your teeth is exactly what you should expect for your dog's or cat's dental care. The same therapeutic advances in human dentistry are available today in veterinary dentistry, but it all begins with a good at-home oral hygiene program. Daily toothbrushing of your dog's or cat's teeth remains the "gold standard" of at-home oral hygiene. Starting the daily routine at an early age facilitates this practice and will strengthen the bond between you and your pet. Increasing the familiarity of your pet to having his or her mouth opened and examined has the added benefit of making veterinary exams much less stressful and it even allows for the earlier detection of more serious oral diseases by you at home.